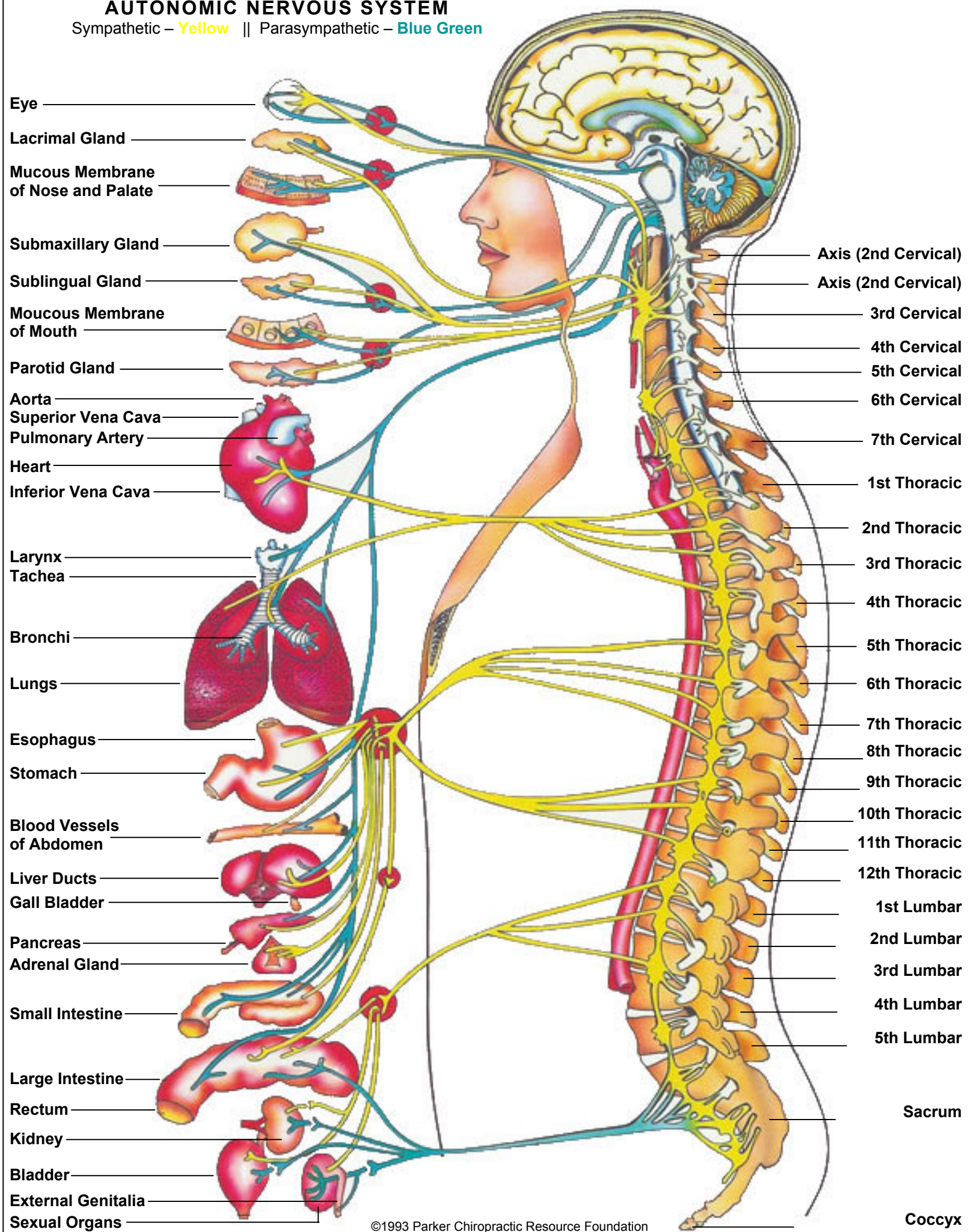


AUTONOMIC NERVOUS SYSTEM

Sympathetic – Yellow || Parasympathetic – Blue Green



- Eye
- Lacrimal Gland
- Mucous Membrane of Nose and Palate
- Submaxillary Gland
- Sublingual Gland
- Mucous Membrane of Mouth
- Parotid Gland
- Aorta
- Superior Vena Cava
- Pulmonary Artery
- Heart
- Inferior Vena Cava
- Larynx
- Trachea
- Bronchi
- Lungs
- Esophagus
- Stomach
- Blood Vessels of Abdomen
- Liver Ducts
- Gall Bladder
- Pancreas
- Adrenal Gland
- Small Intestine
- Large Intestine
- Rectum
- Kidney
- Bladder
- External Genitalia
- Sexual Organs

- Axis (2nd Cervical)
- Axis (2nd Cervical)
- 3rd Cervical
- 4th Cervical
- 5th Cervical
- 6th Cervical
- 7th Cervical
- 1st Thoracic
- 2nd Thoracic
- 3rd Thoracic
- 4th Thoracic
- 5th Thoracic
- 6th Thoracic
- 7th Thoracic
- 8th Thoracic
- 9th Thoracic
- 10th Thoracic
- 11th Thoracic
- 12th Thoracic
- 1st Lumbar
- 2nd Lumbar
- 3rd Lumbar
- 4th Lumbar
- 5th Lumbar
- Sacrum
- Coccyx